

# First-in-human implantation of the Topaz transcatheter tricuspid valve replacement system

Emmanuel Teiger<sup>1\*</sup>, MD, PhD; Mohammed Nejjari<sup>2</sup>, MD; Pascal Lim<sup>1</sup>, MD; Tobias Ruf<sup>3</sup>, MD; Philipp Blanke<sup>4</sup>, MD; Ulrich Schäfer<sup>5</sup>, MD; Hendrik Treede<sup>6</sup>, MD, PhD; Romain Gallet<sup>1</sup>, MD, PhD; Julien Dreyfus<sup>2</sup>, MD

1. Cardiology Department, Henri Mondor University Hospital, Assistance Publique-Hôpitaux de Paris, Créteil, France; 2. Cardiology Department, Centre Cardiologique du Nord, Saint-Denis, France; 3. Zentrum für Kardiologie, Universitätsmedizin Mainz, Johannes Gutenberg Universität, Mainz, Germany; 4. Department of Radiology, St Paul's Hospital & University of British Columbia, Vancouver, BC, Canada; 5. Department of Internal Medicine, Marienkrankenhaus, Hamburg, Germany; 6. Department of Cardiac Surgery, University Hospital Mainz, Mainz, Germany

## Introduction

Severe tricuspid regurgitation (TR) is frequent and associated with poor outcomes<sup>1</sup>. Nevertheless, many patients are declined for surgery because of prohibitive surgical risks. In this setting, transcatheter tricuspid valve (TV) intervention may be a less invasive option. Transcatheter edge-to-edge repair (TEER) has been the most used approach so far<sup>2</sup>; however, transcatheter tricuspid valve replacement (TTVR) might be a more attractive strategy. Indeed, besides providing an alternative for patients whose anatomies are not suitable for TEER (due to large coaptation gaps or short/retracted septal leaflets), TTVR procedures are likely to be less challenging and more reproducible, as demonstrated in the first-in-human trials<sup>3</sup>.

## Methods

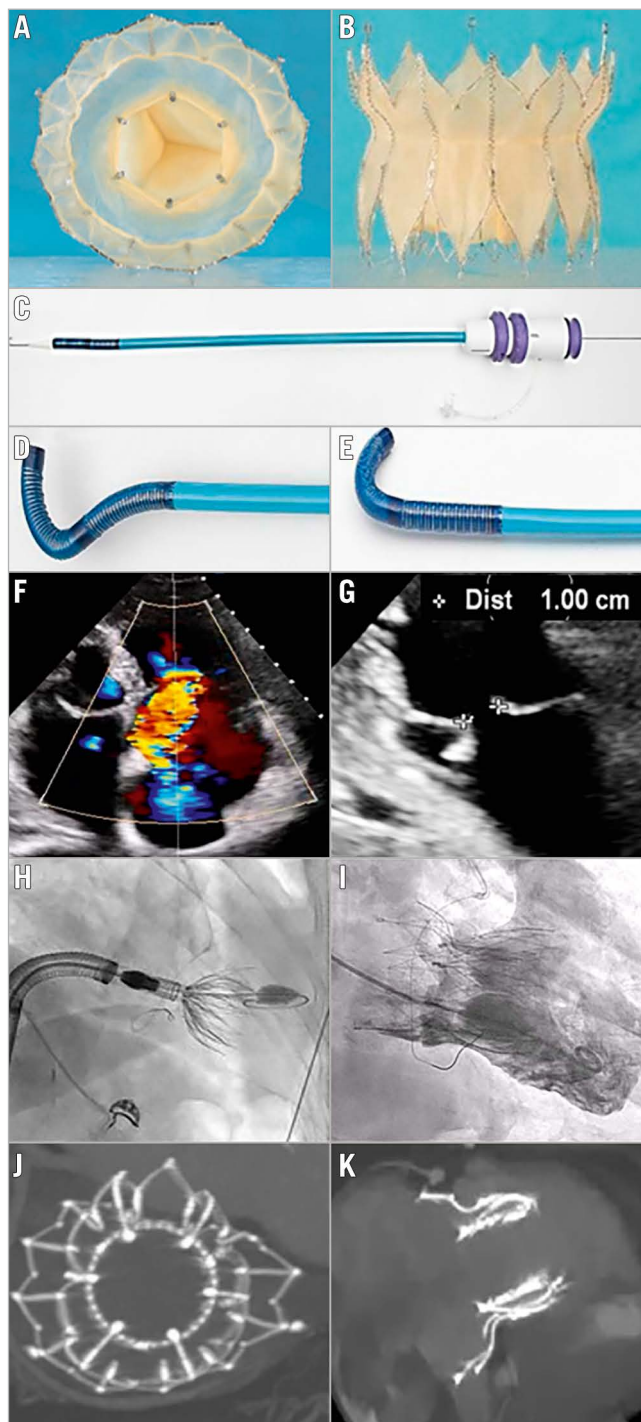
The Topaz transfemoral tricuspid heart valve replacement system (TRiCares) is a novel orthotopic self-expanding TTVR system designed with a two-stent frame made of nitinol. The outer

stent provides a sealed anchoring into the native tricuspid apparatus while protecting the inner stent, which contains the valve, from any deformation caused by the contraction of the right ventricle (RV). The stiffer inner stent houses the three-leaflet valve made from porcine pericardium, which acts independently of the outer stent, thus allowing it to maintain a circular shape and full valve integrity. The system is delivered via the femoral vein through a 29 Fr steerable introducer, currently with no possibility of recapture. The steerable introducer is first brought into the right atrium and oriented toward the tricuspid annulus. The crimped valve is then advanced to the apex of the RV and deployed in a two-step procedure, first the ventricular part of the valve and then the atrial part. The anchoring mechanism does not rely on radial force but on a layer of anchors located below the annulus level. Therefore, no oversizing of the valve is needed. To date, only one size of the valve is available, which allows treatment of an annulus diameter <45 mm based on diastolic computed tomography (CT) scan measurements.

\*Corresponding author: Cardiology Department, Henri Mondor University Hospital, 51 Avenue du Maréchal de Lattre de Tassigny, 94000 Créteil, France. E-mail: emmanuel.teiger@aphp.fr

We herein report the first two cases of compassionate use of the TRiCares Topaz transfemoral tricuspid heart valve replacement system for the treatment of TR. These two cases were

approved by the French authorities (Agence nationale de sécurité du médicament et des produits de santé [ANSM]; Ref. No. 2100459) (Figure 1).



**Figure 1.** Topaz orthotopic transcatheter tricuspid valve replacement for severe TR. Topaz system: a two-stent design, self-expanding prosthesis with 3 porcine pericardium leaflets; the outer stent adapts to the anatomy while the inner stent is more rigid, thus maintaining a circular shape. A) En face view; B) side view. C, D & E) Double-curve steerable sheath for transvenous femoral access. F) Colour Doppler view of the preprocedural torrential tricuspid regurgitation of patient 2 (all the following images are also for patient 2). G) Two-dimensional echographic view of the tricuspid valve coaptation defect. H) Fluoroscopic view of valve deployment. I) Right ventricular angiography immediately after valve deployment. J & K) Post-procedural CT showing the round inner stent linked to the outer stent that conforms to the patient's anatomy. CT: computed tomography; TR: tricuspid regurgitation

## Results

The two procedures were performed in June 2021. The patients were 70-year-old (patient 1) and 86-year-old (patient 2) females. They presented with massive and torrential functional TR<sup>1</sup> due to tricuspid annulus dilatation related to chronic atrial fibrillation. However, both were declined for surgery by the local Heart Teams because of prohibitive surgical risks with TRI-SCOREs of 5 (intermediate risk) and 6 (high risk), respectively<sup>4</sup>, and were not considered suitable for TEER owing to excessive coaptation gaps<sup>5</sup>.

Interventions were performed under general anaesthesia, using a transvenous femoral approach and guided by fluoroscopy and transoesophageal echocardiography. Procedural success (defined as implantation of the valve at the intended position without migration or significant paravalvular leak) was achieved in both cases, with a short procedure time (18 and 12 minutes, respectively, from delivery system in to delivery system out) and with no adverse events. Immediate haemodynamic results were excellent, with good valve deployment at the intended annular position, a mean transvalvular gradient of 2 mmHg in both patients, no residual TR and no paravalvular regurgitation. The two patients were discharged on day four and, given the setting of atrial fibrillation, remained on a non-vitamin K oral anticoagulant.

## Discussion

No death or complication and, notably, no rehospitalisation for heart failure occurred before the post-procedure 3-month follow-up. Transthoracic echocardiography at 3 months showed sustained haemodynamics with no residual TR and an unchanged mean transvalvular gradient (2 mmHg for both patients). However, while there was complete resolution of TR, RV function decreased at three months in both patients (tricuspid annular plane systolic excursion [TAPSE]: 18 mm to 11 mm in patient 1 and 14 mm to 11 mm in patient 2). The three-month CT scan did not reveal any valve thrombosis. Clinical improvement was significant, with an improvement in New York Heart Association (NYHA) functional status from Class III to Class I in both patients. Moreover, in patient 1, the furosemide dose was decreased from 500 mg to none, and the right heart failure symptoms (oedema and jugular congestion) present at baseline were not present at 3 months. Finally, no conduction abnormalities were observed during follow-up.

## Limitations

As further investigations are needed, the TRICURE first-in-human trial is planned to start soon.

## Conclusions

This first-in-human experience with the Topaz TTVR confirms feasibility and safety, abolishing TR with an effective associated short-term clinical improvement.

## Conflict of interest statement

T. Ruf is a consultant and proctor for TRiCares, Abbott Laboratories, and Edwards Lifesciences. P. Blanke is a shareholder of TRiCares. U. Schäfer is a shareholder of TRiCares. H. Treede is a shareholder of TRiCares. R. Gallet is a shareholder of TRiCares. P. Lim is the founder and a shareholder of TRiCares. The other authors have no conflicts of interest to declare.

## References

- Messika-Zeitoun D, Verta P, Gregson J, Pocock SJ, Boero I, Feldman TE, Abraham WT, Lindenfeld J, Bax J, Leon M, Enriquez-Sarano M. Impact of tricuspid regurgitation on survival in patients with heart failure: a large electronic health record patient-level database analysis. *Eur J Heart Fail.* 2020;22:1803-13.
- Taramasso M, Benfari G, van der Bijl P, Alessandrini H, Attinger-Toller A, Biasco L, Lurz P, Braun D, Brochet E, Connelly KA, de Bruijn S, Denti P, Deuschl F, Estevez-Loureiro R, Fam N, Frerker C, Gavazzoni M, Hausleiter J, Ho E, Juliard JM, Kaple R, Besler C, Kodali S, Kreidel F, Kuck KH, Latib A, Lauten A, Monivas V, Mehr M, Muntané-Carol G, Nazif T, Nickening G, Pedrazzini G, Philippon F, Pozzoli A, Praz F, Puri R, Rodés-Cabau J, Schäfer U, Schofer J, Sievert H, Tang GHL, Thiele H, Topilsky Y, Rommel KP, Delgado V, Vahanian A, Von Bardeleben RS, Webb JG, Weber M, Windecker S, Winkel M, Zuber M, Leon MB, Hahn RT, Bax JJ, Enriquez-Sarano M, Maisano F. Transcatheter Versus Medical Treatment of Patients With Symptomatic Severe Tricuspid Regurgitation. *J Am Coll Cardiol.* 2019;74:2998-3008.
- Fam NP, von Bardeleben RS, Hensey M, Kodali SK, Smith RL, Hausleiter J, Ong G, Boone R, Ruf T, George I, Szerlip M, Nábauer M, Ali FM, Moss R, Bapat V, Schnitzler K, Kreidel F, Ye J, Deva DP, Mack MJ, Grayburn PA, Peterson MD, Leon MB, Hahn RT, Webb JG. Transcatheter Tricuspid Valve Replacement With the EVOQUE System: A Multicenter, Observational, First-in-Human Experience. *JACC Cardiovasc Interv.* 2021;14:501-11.
- Dreyfus J, Audureau E, Bohbot Y, Coisne A, Lavie-Badie Y, Bouchery M, Flagiello M, Bazire B, Eggenspieler F, Viau F, Riant E, Mbaki Y, Eyharts D, Senage T, Modine T, Nicol M, Doguet F, Nguyen V, Le Tourneau T, Tribouilloy C, Donal E, Tomasi J, Habib G, Selton-Suty C, Raffoul R, Lung B, Obadia JF, Messika-Zeitoun D. TRI-SCORE: a new risk score for in-hospital mortality prediction after isolated tricuspid valve surgery. *Eur Heart J.* 2022;43:654-62.
- Ruf TF, Hahn RT, Kreidel F, Beiras-Fernandez A, Hell M, Gerdes P, da Roche E Silva JG, Vosseler M, Geyer M, Tamm A, Münzel T, von Bardeleben RS. Short-Term Clinical Outcomes of Transcatheter Tricuspid Valve Repair With the Third-Generation MitraClip XTR System. *JACC Cardiovasc Interv.* 2021;14:1231-40.